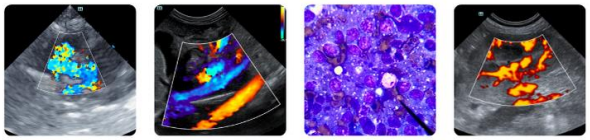

SonoPath.com info@sonopath.com 1.800.838.4268

PATIENT
Max Taylor

SPECIES
Canine

BREED
Pomeranian

SEX
MN

AGE
9 y

WEIGHT
3.6 kg

INTERPRETED BY
Keith Blass, DVM, MS, DACVIM (Cardiology)

IMAGING PERFORMED BY
Dr. Sammi Fuller

HOSPITAL NAME
Hart Family VC

REFERRING VET
Dr. Fuller

INVOICE

DATE
12/31/25

PRESENTING CLINICAL SIGNS

Grade 4/6 murmur. Coughing regularly.

ECHOCARDIOGRAPHIC FINDINGS

2D, M-mode, and Doppler study.

There is moderate left atrial dilation. The mitral valve leaflets are thickened and exhibit systolic prolapse. There is Doppler evidence of mitral regurgitation present. There is mild left ventricular dilation. Left ventricular systolic function is hyperdynamic. The aorta and aortic valve are normal. Right atrial and right ventricular dimensions are normal. The tricuspid valve leaflets are mildly thickened, and there is Doppler evidence of tricuspid regurgitation present. The pulmonary artery and pulmonic valve are normal. No shunting lesions are visualized. No pericardial effusion or cardiac masses are seen.

An rare arrhythmia is present.

LA – 28.1 mm
LVIDd – 22.8 mm
LVIDs – 12.3 mm
FS – 46%
RA – 14.4 mm
LVOT – 0.89 m/s
RVOT – 0.75 m/s

ASSESSMENT/RECOMMENDATIONS

Degenerative mitral and tricuspid valve disease

This examination demonstrates regurgitation of blood across Max's mitral and tricuspid valves resulting from degenerative valve disease. Max's tricuspid valve disease is mild, and appears to be well-compensated at this time. His mitral valve disease is more advanced, as Max has moderate secondary dilation of his left atrium and mild dilation of his left ventricle, though his left ventricular systolic function is well-preserved. Given the presence of moderate left atrial dilation, it's possible that mainstem bronchial compression could be contributing to Max's cough, though thoracic radiographs are recommended to evaluate for this, as well as other possible causes of coughing. Max's risk for the development of other clinical signs secondary to his mitral valve disease, such as exercise intolerance, syncope, and labored breathing, is moderately increased, therefore, careful monitoring for these is recommended.

A rare arrhythmia is seen during this exam, and an ECG is recommended for further evaluation.

I recommend starting Max on pimobendan (1.25 mg am, 0.625 mg pm), as this medication should help to slow the progression of his valvular diseases. Recommended therapy for Max's cough would ideally be based on the results of thoracic radiography.

A recheck echocardiogram is recommended in 9 months.

PATIENT

Max Taylor

SPECIES

Canine

BREED

Pomeranian

SEX

MN

AGE

9 y

WEIGHT

3.6 kg

INTERPRETED BY

Keith Blass, DVM, MS, DACVIM (Cardiology)

IMAGING PERFORMED BY

Dr. Sammi Fuller

HOSPITAL NAME

Hart Family VC

REFERRING VET

Dr. Fuller

INVOICE

DATE

12/31/25

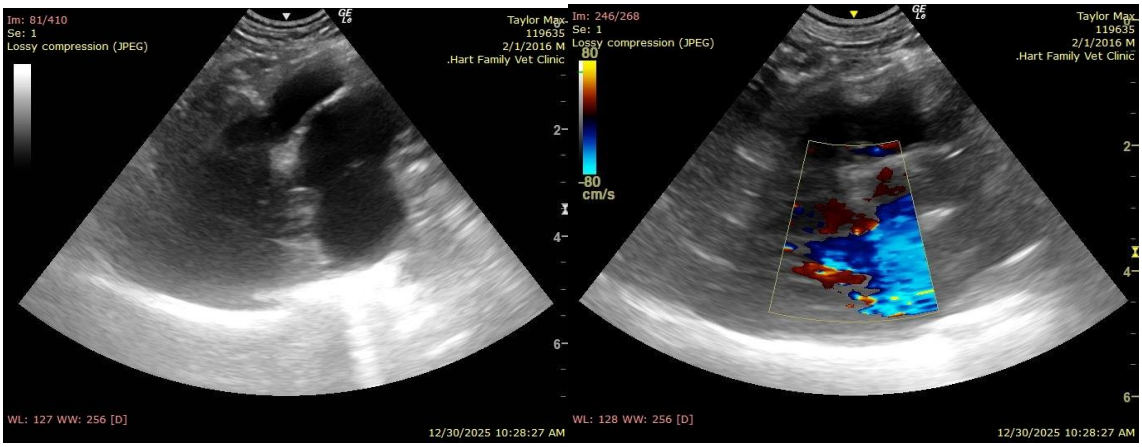

The information and recommendations provided are based on the images presented by the referring veterinarian/sonographer. No evaluation can be communicated regarding pathology that was not visible in the image/video clips provided.

Thank you for this referral. If the clinical or image interpretation does not parallel your findings or if I can be of any further assistance please contact me.

Keith Blass, DVM, MS, DACVIM (Cardiology)

info@SonoPath.com